Accidental Familial Electrocution In A Wet Agricultural Field: A Case Report

Azmath Tabassum*, B.V. Naga Mohan Rao*, V.Jithin Laxmi Narayana*, Nishanth V.S. *, M.Niharika *, Kapil . D*

* Department of Forensic Medicine and Toxicology, Government Medical College, Nizamabad, Telangana, India

Corresponding author:
Dr. Azmath Tabassum | Email:azmath2608@gmail.com
Received: February 10, 2026; Accepted: March 01, 2026 DOI: https://doi.org/10.66644/AJFM.20250205

Abstract:

Unnatural deaths occurring in open environments pose significant challenges to medicolegal investigation, especially in the absence of eyewitnesses or obvious external injuries. Electrocution deaths may closely mimic homicide, poisoning, or animal envenomation, particularly when skin resistance is reduced due to environmental factors such as water. This is a case of three sudden deaths in a single family found in a wet agricultural field, initially suspected to be homicide or mass poisoning. Meticulous autopsy examination, ancillary investigations, histopathology, and crime scene correlation revealed accidental electrocution due to contact with a damaged overhead electric line through a wet wooden stick. This case highlights the indispensable role of integrated forensic investigation in establishing cause and manner of death and ruling out foul play.

Keywords: Electrocution, Histopathology, Crime scene investigation, Accidental death

Introduction:

Investigation of sudden unnatural deaths in open environments is often complex specially in the absence of clear external injuries, witnesses or reliable circumstantial evidence. In such cases, medicolegal autopsy plays a very important role in establishing the cause of death and guiding the direction of legal investigation. Electrocution deaths, particularly in wet environments, may present with minimal or absent external electrical injury marks, thereby creating diagnostic dilemmas and suspicion of homicide or poisoning.

This case report describes three sudden deaths within a single family found in a wet agricultural field. The initial suspicion ranged from homicide to suicidal poisoning and snakebite. A combination of meticulous autopsy, ancillary investigations, and crime scene investigation ultimately revealed accidental electrocution as the cause of death.

Case Details:

Requisition for autopsy was received from the investigating officer for three deceased individuals belonging to the same family (i.e son, father and mother), found dead in a wet agricultural field. Allegations of homicide were raised by relatives, while police also suspected possible suicidal poisoning due to financial distress or animal bite.

Autopsy Findings

Autopsy of the first body was commenced on 20.02.2025 at Government General Hospital, Nizamabad.

Common findings across all three cases:

- No heavy blunt force injuries.
- No specific characteristic odor.
- No bite marks suggestive of snake or animal bite.
- Chemical analysis of viscera: Negative for poisons.

These findings ruled out poisoning, animal bite and homicide with blunt force trauma.

© Author(s) 2026. Published by the Academy Journal of Forensic Medicine (ISSN: 3107-7633). This is an open-access article distributed under the terms of the Creative Commons Attribution–Non Commercial 4.0 International License (CC BY-NC 4.0), which permits non-commercial use, distribution, and reproduction in any medium, provided the original work is properly cited.

Case 1- Son

Age & Sex: 20-year-old male

Findings:

Electric burn injury measuring 1.5 × 1.5 cm over the palmar aspect of the right ring finger, with dry, hardened base and everted margins. (Figure no. 1).

Electric burn injury measuring 8 × 5 cm over the anterior aspect of the right thigh.(Figure no. 2).

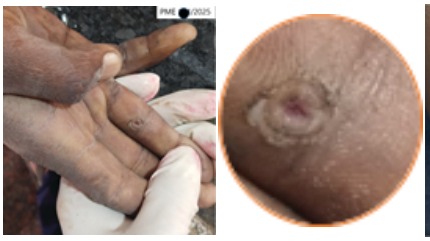

Figure 1

Figure 2

Case 2- Father

Age & Sex: 45-year-old male

Findings:

Electric burn injury measuring 8 × 6 cm over the dorsal aspect of the toes of the left foot.

(Figure no. 3)

Figure 3

Case 3- Mother

Age & Sex: 40-year-old female

Findings: No definite external electric burn injuries detected

In all three cases, internal examination revealed subepicardial and subendocardial hemorrhages of the heart. Figure no. 4, 5 and 6

Figure 4

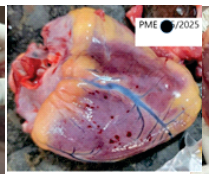

Figure 5

Figure 6

Ancillary Investigations

Viscera and blood sent for chemical analysis which ruled out poisoning.

Samples of skin from suspected electric burn sites, respiratory muscles, and heart tissue were preserved for histopathological examination.

Histopathological Findings

Skin

- Dermo-epidermal separation (clefting)
- Elongation and streaming of epidermal nuclei. (Figure no. 7)
- Coagulative necrosis

Heart

- Myofibre breakup
- Separation of myofibres
- Hemorrhage with extravasation of red blood cells

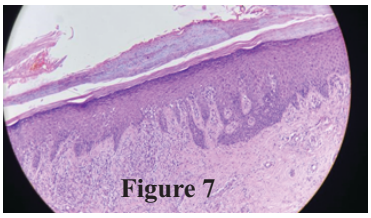

Figure 7

Figure 7 Photomicrographs, haemotoxylin and eosin staining.

I. Dermo-epidermal separation (clefting)
ii. Elongation and streaming of epidermal nuclei.

Crime Scene Investigation

After conducting the autopsy, visited crime scene for restoration. Crime scene inspection revealed that the agricultural field was wet due to recent irrigation. A wet wooden stick was found exactly at the location where the body of the deceased son was lying (Figure no. 10). The same stick was also visible in photographs shared by the investigating officer before the commencement of autopsy.

Further investigation revealed a damaged overhead electric line in proximity to the field. Crime scene restoration revealed that a wet stick held by the son had likely come into contact with the live electric wire. The presence of water in the field significantly reduced skin resistance, allowing electric current to pass through the bodies of the parents, resulting in fatal electrocution of the entire family (Figure no. 8). Crime scene reconstruction revealed that the deceased son was lying in a prone position, directly

Figure 8 Crime scene interpretation; **Figure 9** position of dead bodies at the scene of crime and **Figure 10** Presence of a wet stick at the scene. (From left to right)

below the overhead electric wire, a few meters away from his parents, holding a stick in his right hand. The bodies of the mother and father were found in a supine position, lying close to each other with their lower limbs almost touching. This relative positioning suggests that the son was the initial point of contact with the source of electricity, while the parents likely collapsed simultaneously or sequentially after secondary exposure through the wet environment. The spatial arrangement of the bodies, when correlated with the wet agricultural field, damaged overhead electric line, and autopsy findings, supports accidental electrocution as the cause of death and rules out homicidal or suicidal manner (Figure no. 9).

Discussion:

If the contact with the high-voltage current is not direct, but running through an intermediary object such as a ladder or pole, the burns are chalky white in color, with raised borders and a central crater with yellowish discoloration. [1]

Fatal electrocution may occur with no skin mark as the low skin resistance caused by the water abolishes the possibility of a focal burn.

Studies showed, the histopathological examination findings of skin includes epidermal nuclear elongation, dermo epidermal separation and coagulative necrosis.[2,3] Water lowers the resistance of the skin and electric current density. In that study they had six electrocution deaths in the wet location and the skin did not show obvious gross changes in five cases. On microscopic examination these cases showed nuclear streaming in five cases and one case had a normal microscopic appearance. [3]

The peculiar distortion of nuclei specially at basal layer of epidermis is called nuclear streaming is due to passage of electric current. [4]

Dermo-epidermal separation is a common histopathological finding. Histopathological changes can be used as supportive evidence in giving cause of death in such cases. [5]

The previous studies done in electrocution deaths, histopathological changes in the heart include myofibre break-up, separation of myofibres, and RBC extravasation are diagnostic in electrocution deaths. [6]

It is important to carefully look at the heart and other internal organs during these times to observe certain changes in the heart's histology, such as petechial hemorrhages, waviness of myocardial fibers, squaring and elongation of nuclei, and myocyte vacuolization. Even in the absence of external burns, these results, when combined with the clinical history and environmental context, can offer compelling evidence for electrocution. [7]

In India, statutory safety regulations require overhead conductors to maintain minimum vertical clearances above ground to reduce the risk of accidental contact. Under the Indian Electricity Rules and CEA safety standards, a high-voltage overhead line not spanning a street should be at least 5.2 m above ground, while lines located along or across roadways should generally be at least 6.1 m above ground level. These clearances increase further for extra-high voltage lines with voltage above 33 kV. These clearances are minimum legal requirements meant to prevent accidental contact and ensure public safety.[8] All apparatus and supply lines should be maintained and tested periodically as per the standards. Overhead lines should have a strength of more than 350 kgf.

But in most of the villages, these electric wires can be touched with a raised hand, as they are hanging very low. In many places, electric poles were damaged and wires have become a threat to people lives. As per Deccan Chronicle, over 500 people die due to electrocution every year in Telangana.

Most of the fatalities due to electrocution are accidental or unintentional. Very few are suicidal and homicidal deaths from electrocution. The important cause for world-wide electrocution are poor maintenance of electric equipments, misuse and carelessness. Lack of knowledge of electrical

hazards coupled with lack of safety measures are equally responsible for ED. [9,10,11]

In the diagnosis of electric mark Fourier Transform Infrared (FTIR) spectroscopy can be useful as a complementary tool as demonstrated by Zhang et al.[12]

CONCLUSION:

This case underscores the critical role of forensic medicine experts not only in performing autopsies but also in correlating findings with crime scene investigation. Although individual scene or histopathological findings may be non-specific when interpreted in isolation, the integrated correlation of crime scene reconstruction, autopsy findings, histopathological features, and circumstantial evidence collectively essential in distinguishing accidental deaths from homicidal or suicidal causes. The autopsy, when performed meticulously, remains a reliable tool in uncovering the truth behind unexplained deaths.

Unsafe or poorly maintained overhead electric lines, particularly in open and agricultural environments, constitute a recognized public safety hazard and may lead to fatal electrocution under conducive conditions.

REFERENCES:

1. DiMaio D, DiMaio VJ. Forensic Pathology. CRC Press; 2001.
2. Sukheeja D, Shanmugam J, Subramanian A, Lalwani S. Can a postmortem skin biopsy predict cause of death? J Lab Physicians. 2013 Jul;5(2):121-3. doi: 10.4103/0974-2727.119865. PMID: 24701106; PMCID: PMC3968622.
3. Patil RN, Tijare J, Raut W. Histopathological examination of skin in electrocution deaths: A one-year autopsy study. Indian J Forensic Community Med. 2017;4(4):255-260.
4. Yaggati N, Shashikala P, Rajashree K, Kamaradgi PN. Histomorphological changes of skin in electrocution deaths. IP Arch Cytol Histopathol Res. 2023;7(1):47-53.
5. DiDar Singh Walia1, raminDer Kaur2, JagDiSh gargi3, DalJit Singh4, aKaSh Deep aggarWal5 JCDR
6. Shubha HV, Nirmala CA. Histopathological changes in heart in electrocution deaths. Trop J Path Micro.
7. Datta A, Shukla S. Histopathological lesions in skin & heart following electrocution: a case series. J South India Medicolegal Assoc. 2024;16:23–28.
8. Central Electricity Authority. Central Electricity Authority (Measures Relating to Safety and Electric Supply) Regulations, Chapter VII. New Delhi: Government of India; 2010.
9. Sachil kumar, Anoop K. Verma, Uma Shankar Singh. Electrocution-related mortality in northern India-A 5 year retrospective study. Egyptian Journal of Forensic Sciences 2014;4:1-6.
10. Manish Shrigiriwar, Rajesh Bardale, P.G. Dixit. Electrocution: A six year study of Electrical fatalities, JIAFM 2007;29(2):50-53.
11. Wick R, Gilbert JD, Simpson E, Byard RW. Fatal electrocution in adults –a 30 year study. Med Sci Law.2006;46(2):166-72.
12. Zhang J, Lin W, Lin H, Wang Z, Dong H. Identification of skin electrical injury using infrared imaging: A possible complementary tool for histological examination. PloS One 12(1):DOI:10,1371/journal,pone.0170844.